

EFFECTS OF MESENCEPHALIC LESION ON TESTES, SEMINAL VESICLES AND ADRENAL GLANDS OF ALBINO RATS

M. ABID ALI

Department of Human Physiology,
Faculty of Medicine,
Ahmadu Bello University,
Zaria, Nigeria

(Received on October 13, 1992)

Abstract: The role of mesencephalic reticular formation on testicular structure, seminal vesicles, adrenal glands and kidneys of albino rats was investigated. Mesencephalic reticular formation lesions were produced using two epoxy-coated stainless steel electrodes. Electrolytic lesions resulted in atrophy of the testes, seminal vesicles and adrenal glands. The degree of atrophy was statistically significant in these organs ($P < 0.01$). However, there were no significant changes in the kidneys of lesioned animals. This study strongly suggests that the mesencephalic reticular formation influences the histomorphology of testes, seminal vesicles and adrenal glands.

Key words: mesencephalic reticular formation
seminiferous tubules

testis
seminal vesicles

electrolytic lesion
adrenal gland

INTRODUCTION

The mesencephalic reticular formation (RF) is involved in the mediation of somatic and visceral sensorimotor responses such as eating and drinking, attack, and sexual behaviour (1-6). More recently, Lateral Hypothalamus (LH) and Lateral Preoptic Area (LPA) projections to the RF (7) and RF neuronal input to the LH and LPA have been identified (8-9). Mesencephalic reticular formation activity has been shown to result both in facilitation or inhibition of gonadotrophin secretion in the female rats, (8,10). It has also been demonstrated that discrete lesions in areas of mesencephalic reticular formation influence ovarian function, female reproductive behaviour, (8,11). However, the influence of similar lesions on male reproductive tract, particularly the testis, seminal vesicles, and on adrenal glands has not yet been documented.

Therefore it has been considered worthwhile to investigate and clarify the effects, if any, of discrete lesions of mesencephalic reticular formation on the testicular structure, seminal vesicles, adrenal glands and kidneys.

METHODS

Experiments were performed on male adult albino rats, Wistar strain weighing between 270-350 G.

The animals were maintained on rat feed and water *ad libitum* throughout the period of study.

The animals were randomly divided into two groups of ten rats each as follows:

GROUP I - Sham-operated rats which served as control.

GROUP II - Experimental rats in which lesions were produced.

Surgical Technique: After anaesthetizing the animals with phenobarbitone sodium (30 mg/kg, ip) two holes were drilled bilaterally in the skull and the electrodes were introduced stereotaxically into the brain. Electrolytic lesions were produced bilaterally in the mesencephalic reticular formation using two epoxy-coated stainless steel electrodes of 0.4 mm diameter and a bared tip of 0.2 mm. A current of 5 mA was delivered for 20 second to produce a discrete lesion of about 1.5 mm diameter. The stereotaxic co-ordinates were: Anterior-posterior = 2.18 mm; Lateral = 1.1 mm; Ventral = 0.8 mm (vide atlas of König and Klippel, (12). After producing the lesions, electrodes were removed and the skin sutured. In control (Sham-operated) rats, electrodes were withdrawn without passing any current.

At the end of the experiment, after 30 days, the

Sham-operated and the lesioned rats were weighed and perfused to fix the tissues in the vital state. The testes were removed, dried on a filter paper and weighed using Mettler electrical balance. In order to see whether changes were reflected in other organs, the seminal vesicles, adrenal glands and kidneys were also removed for study. The testes, and other organs were fixed overnight in Bouins fixative and processed to obtain paraffin sections 4 and 6 μm thick, which were stained with Masson trichromic dye for histological and histomeric studies. Precise location of the lesions were found out from histological examination of reactions of brain fixed in formaline (10%) and stained with thionine and neutral red.

I. Histometry:

Using standard micrometric techniques the following parameters were studied:

1. Size of seminiferous tubules, expressed as their computed area.
2. Density of seminiferous tubules expressed as the number of tubules per unit area (mm^2).
3. The distribution of tubules was estimated according to their size and density of sperm population.
4. Average complete cross section count of the interstitial cells: All the testes were sectioned at right angles to their longitudinal axis at the widest point and a complete cross-sectioned count of interstitial cells was made in both the sham-operated and lesioned rats, (13,14).

- #### II. Changes in size, weight and morphology of seminal vesicles, adrenal glands and kidneys were recorded.

Statistical Analysis: Statistical analysis was performed using student's t-test for paired means. The Sham-operated rats were compared with lesioned animals.

RESULTS

All the rats in groups I (Sham-operated) and groups II (lesioned animals) showed prompt recovery within 2-3 hours after the operative procedures. Some of the animals showed hyperactivity for varying periods

(3-10 days) with marked gnawing movements.

The effects of mesencephalic reticular formation lesion on different organs of albino rats are shown in Table I.

TABLE I: Mesencephalic influence on various organs of albino rats.

	Body weight (g)	Testicular weight (g)	Weight of Seminal Vesicle (g)	Weight of Adrenal gland (g)	Weight of Kidney (g)
Sham-operated rats (Group I)	308.87 \pm 7.60	1.340 \pm 0.08	0.650 \pm 0.021	0.025 \pm 0.001	1.0853 \pm 0.032
Lesioned rats (Group II)	311.25 \pm 7.93	0.701* \pm 0.76	0.341* \pm 0.016	0.012* \pm 0.001	1.0964 \pm 0.0320

The values represent Mean \pm SEM; = P < 0.01 Student t-test

The weight of testis was significantly decreased ($P < 0.01$) in lesioned rats when compared to testicular weight in Sham-operated animals (Fig. 1). The weight

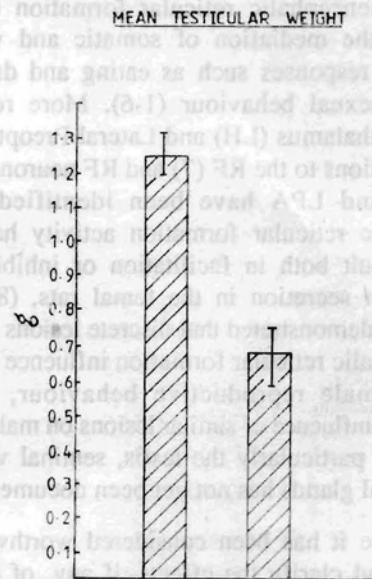


Fig. 1: Influence of Mesencephalic lesion on testicular weight of albino rats. Left bar - control rats; right bar - experimental group.

of the seminal vesicles of lesioned rats was significantly decreased ($P < 0.01$) when compared to those of controlled rats (Fig.2). The adrenal glands of lesioned animals showed marked reduction in weight as

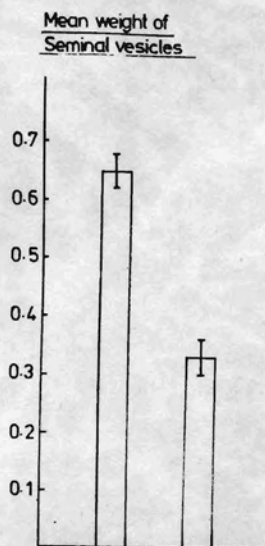


Fig. 2 : Influence of Mesencephalic lesion on weight of seminal vesicles of albino rats.

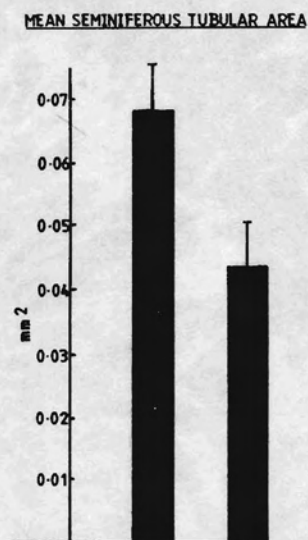


Fig. 4 : Influence of Mesencephalic lesion on seminiferous tubular area of albino rats.

compared to adrenals of sham-operated animals (Fig.3).

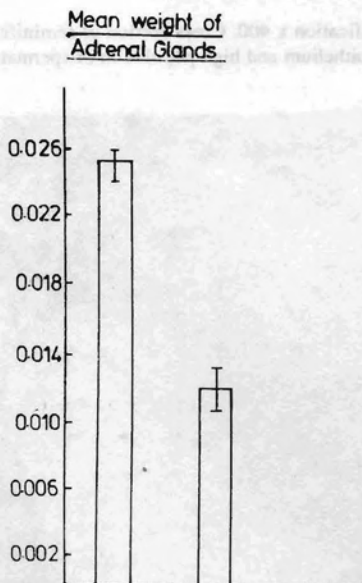


Fig. 3 : Influence of Mesencephalic lesion on weight of adrenal glands of albino rats.

The diameter of seminiferous tubules and their computed areas in lesioned animals were significantly decreased ($P < 0.05$) (Fig. 4). The number of

seminiferous tubules per unit area of lesioned rats was significantly increased ($P < 0.01$) as compared to Sham-operated animals.

The lesioned rats showed depressed spermatogenesis as demonstrated by a general decrease in the number of cells from different generation of germinal epithelium, empty spaces, degeneration of spermatogonia (hyperstained nuclei and nuclei with large vacuoles) and degeneration of young spermatids

TABLE II: Mesencephalic influence of testicular histomorphology.

	Semi-ferous tubular Area (mm²)	No. of tubules per sq mm	Distribution of Tubules according to sperm density			No of interstitial cells per cross-section
			High (above 200)	Medium (100-200)	Low (below 100)	
Sham-operated rats (Group I)	0.068 ± 0.007	20.60 ± 0.46	62.60 ± 1.86	30.14 ± 1.53	9.62 ± 1.53	916.620 ± 12.342
Lesioned rats (Group II)	± 0.044*	28.17*	2.60*	22.01*	78.46*	424.260*
	± 0.078	± 0.76	± 0.06	± 5.78	± 7.62	± 8.730

The values represent Mean ± SEM; = $P < 0.01$ - Student t-test.

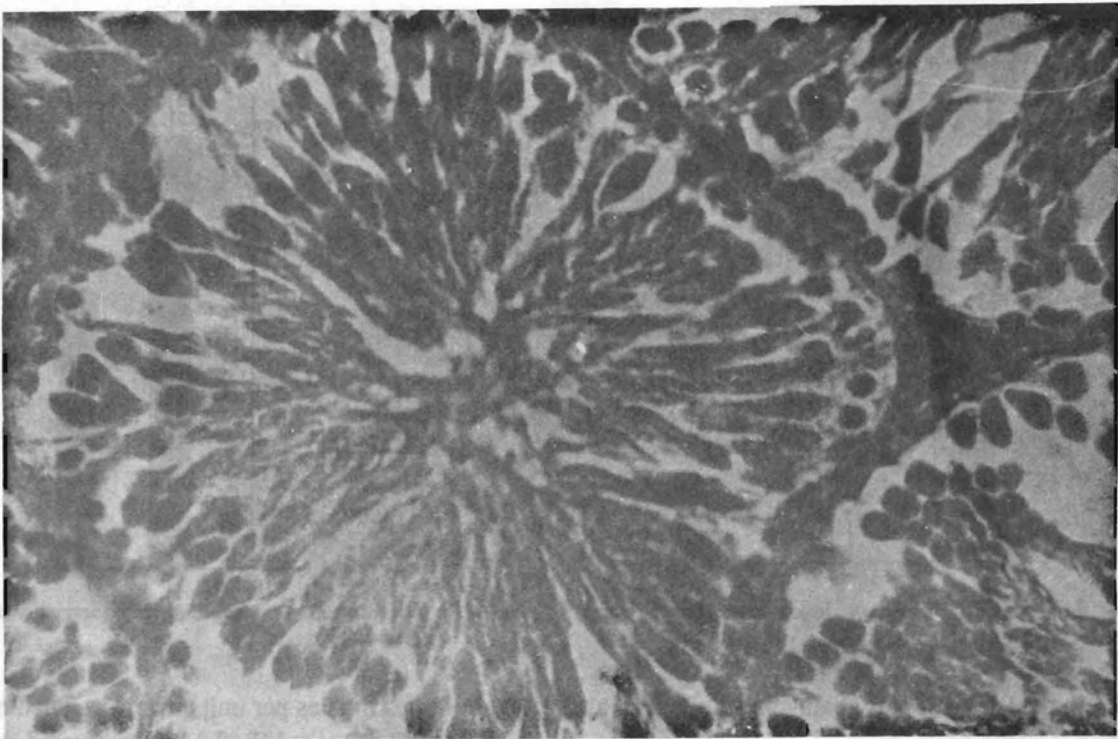


Fig. 5: Testes fixed in Bouins's fixative and stained with Masson trichromic dye Magnification x 400. Cross section of seminiferous tubules from: (a) Sham-operated rats autopsied at 30 days showing healthy germinal epithelium and high population of spermatozoa.

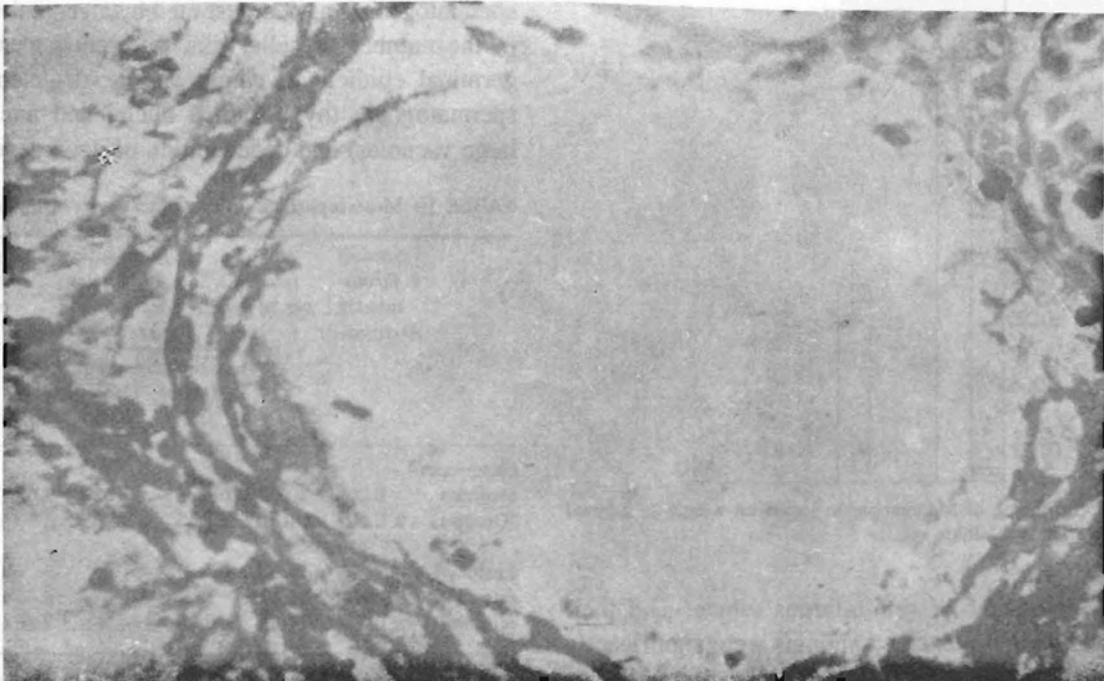


Fig. 5: (b) Lesioned rats autopsied at 30 days showing degeneration of germinal epithelium with absence of spermatozoa.

in comparison with those of control rats which had healthy germinal epithelium and high population of spermatozoa (Fig. 5a and b). The average complete cross section count of interstitial cells was significantly reduced ($P < 0.01$) in lesioned animals as compared to Sham-operated rats. Table II, shows the mesencephalic influence on testicular histomorphology, and spermatogenesis.

No appreciable changes were observed in the body weight and kidneys of lesioned animals and there were no significant changes in the food intake of lesioned rats.

The approximate location of the lesion area in discrete brain regions of group II rats on frontal planes of anterior posterior level is shown in (Fig. 6) using the stereotaxic atlas, of König and Klippel (12).

DISCUSSION

The present study demonstrates that bilateral electrolytic lesion in midbrain reticular formation affect the gonads and adrenal glands and result in marked reduction in testicular weight, seminiferous tubular area and spermatogenesis, and also significant reduction in the weight of seminal vesicles and adrenal glands ($P < 0.01$). No appreciable changes were observed in the body weight and food intake of experimental animals. It would thus seem that the effects are specific since the reduction in size of gonads and adrenal glands is not reflected in other organs such as kidneys and raise the possibility of the influence being mediated through neuro-humoral pathways controlling the activity of steroid hormone producing glands viz. the testes and adrenal glands.

Hypothalamus is well known to contain the basic neuronal elements for the secretion of hypophyseal

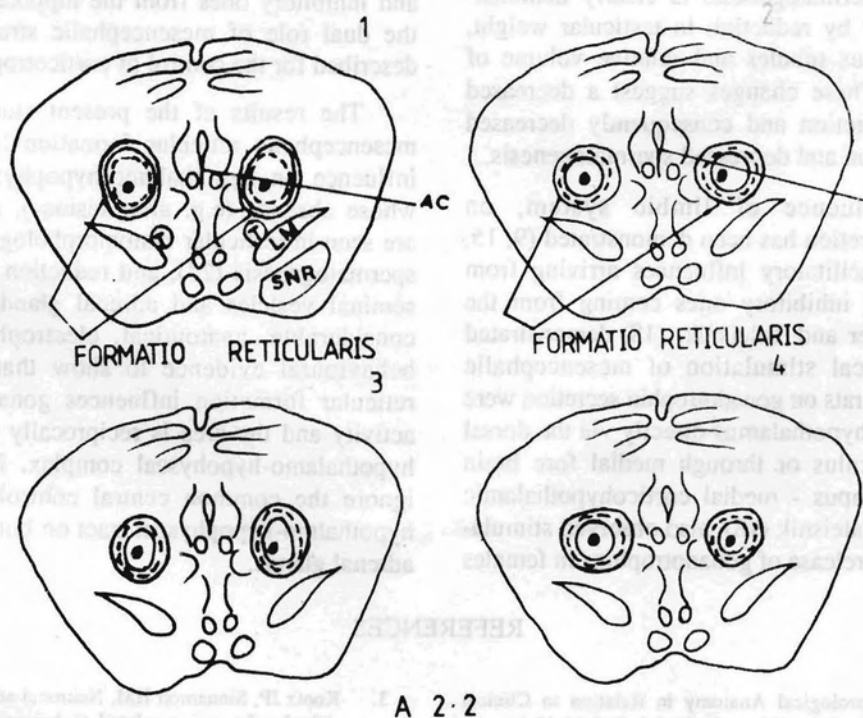


Fig. 6: Shows symmetrical bilateal lesions of mesencephalic reticular formation on schematic coronal section. A-P Co-ordinates 2180 U (according to König and Klippel Atlas). AC = Aqueduct ; LM = Medial Lemniscus ; SNR = Substantia Nigra

gonadotropin. However, extra hypothalamic neuronal structures are essential for the coordination of extero and interoceptive stimuli affecting the hypothalamic function. It has been shown that electrochemical stimulation of amygdaloid nuclei induce ovulatory response in rats which were in persistent estrous due to exposure to continuous illumination(15). Electrochemical stimulation of hippocampus inhibited spontaneous ovulation (16).

The importance of studying the diameters of seminiferous tubules is in accordance with the observation made earlier by Coombs and Marshall, (17) who found a distinct diminution in the diameter of seminiferous tubules within two months of hypophysectomy. The diminution in diameter of seminiferous tubules and their computed areas in the present study is highly significant ($P < 0.05$), and comparable with that observed by Coombs and Marshall (17).

Depressed Spermatogenesis is clearly demonstrated in this study by reduction in testicular weight, size of seminiferous tubules and relative volume of interstitial cells. These changes suggest a decreased gonadotrophin secretion and consequently decreased androgen production and depressed spermatogenesis.

A dual influence of limbic system, on gonadotrophin secretion has been demonstrated (9, 15, 16, 18, 19-21), facilitatory influences arriving from the amygdala and inhibitory ones coming from the hippocampus. Career and Taleisnik, (18) demonstrated that electrochemical stimulation of mesencephalic structure in female rats on gonadotrophin secretion were transmitted to the hypothalamus directly via the dorsal longitudinal fasciculus or through medial fore brain bundle - hippocampus - medial corticohypothalamic tract. Career and Taleisnik (18), also observed stimulatory effects on the release of gonadotrophins in females

rats after mesencephalic stimulation in the dorsal tegmentum, and inferior to aqueductal grey. Morphine, atropine and pentobarbital, administered to rats in doses that blocked ovulation, also elevated midbrain threshold for E.E.G. activation (22). Intracerebral injections of morphine and metenkephalinamide in mesencephalic reticular formation had been shown to alter hypothalamo - pituitary axis and LH secretion in male and female rats (22-24).

It has been demonstrated that remarkable changes in vaginal cytology occurred on stimulation of mesencephalic reticular formation (20). Sen et al (20) also observed rupture of graffian follicle, ovulation, increase in ovarian weight. Therefore these authors suggested that midbrain reticular formation controls the LH release from the anterior pituitary in the same way as ACTH, and intact median eminence is essential for this effect. A dual influence of limbic system on gonadotrophin secretion has been demonstrated, facilitatory effects arriving from the amygdala (22), and inhibitory ones from the hippocampus. Similarly the dual role of mesencephalic structures has been described for the control of corticotropin release (23).

The results of the present study indicate that mesencephalic reticular formation has a facilitatory influence on hypothalamo-hypophyseal axis and in whose absence (e.g. after lesions), atrophic changes are seen in testicular histomorphology with decreased spermatogenesis (24), and reduction in the weight of seminal vesicles and adrenal glands. There is thus considerable, anatomical, electrophysiological and behavioural evidence to show that mesencephalic reticular formation influences gonadal and adrenal activity and the area is reciprocally connected to the hypothalamo-hypophyseal complex. It is not easy to ignore the common central controlling axis of the hypothalamo-hypophyseal tract on both the gonads and adrenal glands.

REFERENCES

1. Brodal A. Neurological Anatomy in Relation to Clinical Medicine 1981; 3rd edition, Oxford; Oxford University Press.
2. Carter HF. Mesencephalic participation in the control of sexual behaviour in the femal rat. *J Comp Neurol* 1978; 92: 877-886.
3. Kootz JP, Sinnamon HM. Neuronal activity in the midbrain reticular formation related to behavioural habituation and sensitization. *Brain Res Bull* 1978; 3: 533-540.
4. Lyon MM, Halpern, Mintz E. The significance of the mesencephalon for coordinated feeding behaviour. *Acta neurol scand* 1965; 44: 323-346.

5. Pitman QJHW, Blume RE, Kearney, Renaud LP. Influence of midbrains stimulation on the excitability of neurons in the medial hypothalamus of the rat. *Brain Res* 1979; 174: 39-53;
6. Waldbilg RJ. Attack, eating, drinking, and gnawing elicited by electrical stimulation of rat mesencephalon and pons. *J Comp Physiol psychol* 1975; 89: 200-212.
7. Swanson LW. An autoradiographic study of the efferent connections of the preoptic region in the rat. *J Comp Neurol* 1976; 167: 227-256.
8. Barone FCMJ, Wayner SL, Scharoun R, Guevara-Aguilar and H.U. Aguilar-Baturomi. Afferent connections to the lateral hypothalamus: A borseradish peroxidase study in the rat. *Brain Res Bull* 1981; 7: 75-88.
9. Barone FCMJ, Wayner I, Zarco de Cordnado, Tsai WH. Mesencephalic reticular formation effects on hypothalamic neuronal activity. *Brain Research Bulletin* 1981; 7: 419-425.
10. Groves PM, Miller SW, Parker MV. Habituation and sensitization of neuronal activity on the reticular formation of the rat. *Physiol Behav* 1972; 8: 589-593.
11. Crossman SP. Correlative analysis of ingestive behaviour and regional amino acid depletions after surgical transections of neural pathways in mesencephalon, diencephalon, and straitum. In: Control Mechanisms of Anorectic Drugs, edited by S. Garatini and R. Samanin. New York; Raven Press. 1978, pp 1-38.
12. Konig JRF, Klippel RA. The Rat Brain: A Stereotaxic Atlas of the Forebrain and Lower parts of the Brain Stem Baltimore: Williams and Wilkins, 1963.
13. Baillie AH Biology of Leydig cells: histochemical and histological changes following high epididymal obstruction. *J Endocrinol* 1960; 20: 339-344.
14. Kothari LK, Srivastava DK, Mishra Pushpa, Patri. MK. Total Leydig cell volume and its estimation in dogs and in models of Testis. *Anat Rec* 1972; 174: 259-264.
15. Velasco ME, Taleisnik S. Release of gonadotrophins induced by amygdaloid stimulation in the rat. *Endocr* 1969a; 84: 132-139.
16. Velasco ME, Taleisnik S. Effects of hippocampal stimulation on the release of gonadotrophins. *Endocr* 1969b; 85: 1154-1159.
17. Coombs CFJ, Marshall AJ. The effects of hypophysectomy on internal rhythm in birds and mammals. *J Endocr* 1956; 13: 107-111.
18. Career HF, Taleisnik S. Effects of mesencephalic stimulation on the release of gonadotrophins. *J Endocr* 1970; 48: 527-537.
19. Cowan WM, Guillery EW, Powel TPS. The origin of mamillary peduncle and other hypothalamic connections from the midbrain. *J Anat (Lond)* 1964; 98: 345-363.
20. Sen RN, Singh B, Saranghi NN. The pituitary gonadotrophic releasing activity of midbrain reticular formation. *Indian J Physiol Pharmacol* 1967; 12: 34.
21. Taleisnik S, Velasco ME, Astrada JJ. Effects of hypothalamic differentiation in the control of lutenizing hormone secretion. *J Endocr* 1970; 46: 1-7.
22. Sawyer CH, Critchlow BV, Barrchough CN. Mechanism of blockade of pituitary activation in the rat by morphine, atropine and barbiturates. *Endocr* 1955; 57: 345-350.
23. Mangili G, Motta M, Martini L. Control of adrenocorticotropin secretion. *Neuro-endocrinology* 1966; 94: 1004-1011.
24. Abid Ali M. Effects of Mesencephalic lesion on the histomorphology of testis and spermatogenesis. *Indian J Physiol Pharmacol* 1986; 30: 11-21.